



Laparoscopy of the genitourinary tract of small ruminants

D.P. Vrisman¹, E. Choaire¹, F. Strucher¹, M.S. Oliveira¹, T.M.B. Ribas¹, L.N. Coutinho²,
R.S.G. Mariano², M.G. Oliveira¹, W.R.R. Vicente², M.A.M. Silva³, P.P.M. Teixeira^{1,2,4}

¹Veterinary Medicine Department, Middle-West State University (UNICENTRO), Guarapuava, PR, Brazil.

²Faculty of Agricultural Sciences and Veterinary (FCAV), São Paulo State University "Júlio de Mesquita Filho" (UNESP), Jaboticabal, SP, Brazil.

³School of Agronomy and Veterinary Medicine, University of Passo Fundo (FAMV/UPF), Passo Fundo, RS, Brazil.

Abstract

Laparoscopic endosurgery is an important tool for small ruminant breeding especially due to its wide versatility, both in reproductive biotechnologies and therapeutic approach. The purpose of this review is to present the applicability and advantages of endosurgery for routine use in small ruminants. Several endosurgical techniques of the genitourinary tract of small ruminants, including artificial insemination, embryo transfer, and oocyte retrieval for IVF, ovariectomy, cystotomy and renal biopsy are approached. The endoscopic techniques can improve the development of potential zootechnical indexes on the short-term period in comparison to traditional approaches.

Keywords: endosurgery treatment, goats, reproductive biotechnologies, sheep.

Introduction

The evident expansion of sheep and goat breeding lead to the need for the development of reproductive biotechnologies for maximizing productivity of livestock, aiming at the production of high genetic pattern and productive animals (Simplicio *et al.*, 2002). Laparoscopy is a minimally invasive technique that allows the exploration of the abdominal and pelvic organs using a transabdominal endoscope and other adapted equipment for endosurgery, allowing it to work with these organs made for both therapeutic and for reproductive biotechnologies (artificial insemination, embryo transfer and laparoscopic ovum pick-up) particularly in small ruminants (Bouré, 2005; Teixeira *et al.*, 2013).

Artificial insemination (AI) is an important reproductive management aspect in sheep breeding due to the specie's short reproductive cycle and calving intervals. Using biotechnologies, high genetic value offspring production can be reached (Bettencourt, 1999). With the employ of embryo transfer (ET), besides the same advantages of AI, it is possible to expand the genetic value and production potential of females, while avoiding mating, and thus, minimizing the transmission of reproductive infectious diseases

(Varago *et al.*, 2009). The ovum pick up (OPU) for *in vitro* production of embryos is an efficient biotechnology, which allows for repeated follicle aspiration sessions at short intervals in adult and prepubertal females following several ovarian stimulation protocols (Wani, 2002; Valasi *et al.*, 2009; Baldassare, 2012; Blash *et al.*, 2012; Crocomo *et al.*, 2012; Teixeira *et al.*, 2011b, 2012).

Although laparoscopy for ovariectomy is not routinely performed, it is used for herd management, weight gain of the animals, improvement of the quality of carcass, recovery of gametes and for researches on reproductive technology (Teixeira *et al.*, 2011a). Laparoscopy is also used for laparoscopic-assisted cystotomy, presenting benefits such as short duration of anesthesia, fast convalescence and avoidance of urethrostomy/urethrostomy (Gheller, 2008). Moreover, laparoscopic-assisted renal biopsy is useful in studies on pharmacokinetics and toxicology (Toutain *et al.*, 1985).

Based on such relevant facts, the aim of the current study was to review the applicability and advantages of the endosurgery applied to the genitourinary tract of small ruminants.

Artificial insemination

Improvement of the herd is one of the main goals of sheep and goat breeding farms. Regardless of the technique used, the knowledge of ovulation time is critical in order to obtain a success full insemination program. The ovum is usually viable for about 12-24 h (Ax *et al.*, 2004; Ferra and Sereno, 2006). In laparoscopic IA, frozen semen is thawed and deposited directly into the uterus following needle puncture, unlike cervical or trans-cervical AI (Donovan *et al.*, 2004). In order to optimize the technique, synchronization of the estrous cycle of the animals is crucial. Protocols using progestins are usually optimal (Silva, 2009).

For laparoscopic-assisted AI the animals are submitted to general anesthesia and positioned in dorsal recumbence, on a 45° head tilting, which is known as Trendelenburg position (Rabassa *et al.*, 2007; Teixeira *et al.*, 2011b), as shown in Fig. 1 and 2.

⁴Corresponding author: p_paulomt@yahoo.com.br

Phone: +55(42)9912-5588

Received: April 1, 2014

Accepted: August 7, 2014

A two-port technique is used. It is recommended to perform local anesthesia on the two port insertion sites, both caudolateral to the umbilicus. Following a 1-2 cm skin incision, a 5-mm or 10-mm trocar with sharp tip obturator is inserted through the abdominal wall, followed by the establishment of a 5-mmHg CO₂ pneumoperitoneum. Afterwards, a second trocar is inserted using laparoscopic guidance. An insemination pipette with a needle tip is introduced through the second trocar cannula to penetrate the uterine horns and deposit the semen in contact with the uterine mucosa. It is essential to locate the most cranial aspect of the uterus, which presents less blood supply, to insert the

needle perpendicularly to the uterus wall. Semen is injected within the uterine lumen. The laparoscope and the cannulas are removed and the abdominal incisions are closed routinely. Procedure time may take as short as 2-5 min, depending on the experience of the surgeon (Carneiro *et al.*, 2011).

Semen doses should contain about 150-200 x 10⁶ viable spermatozoa. It means that about 15 to 30 sheep can be inseminated with a single ejaculate (Bicudo *et al.*, 2005). In commercial herds, the use of laparoscopic AI is still limited due to the high cost of implementation, learning curve and team formation (Kershaw *et al.*, 2005).

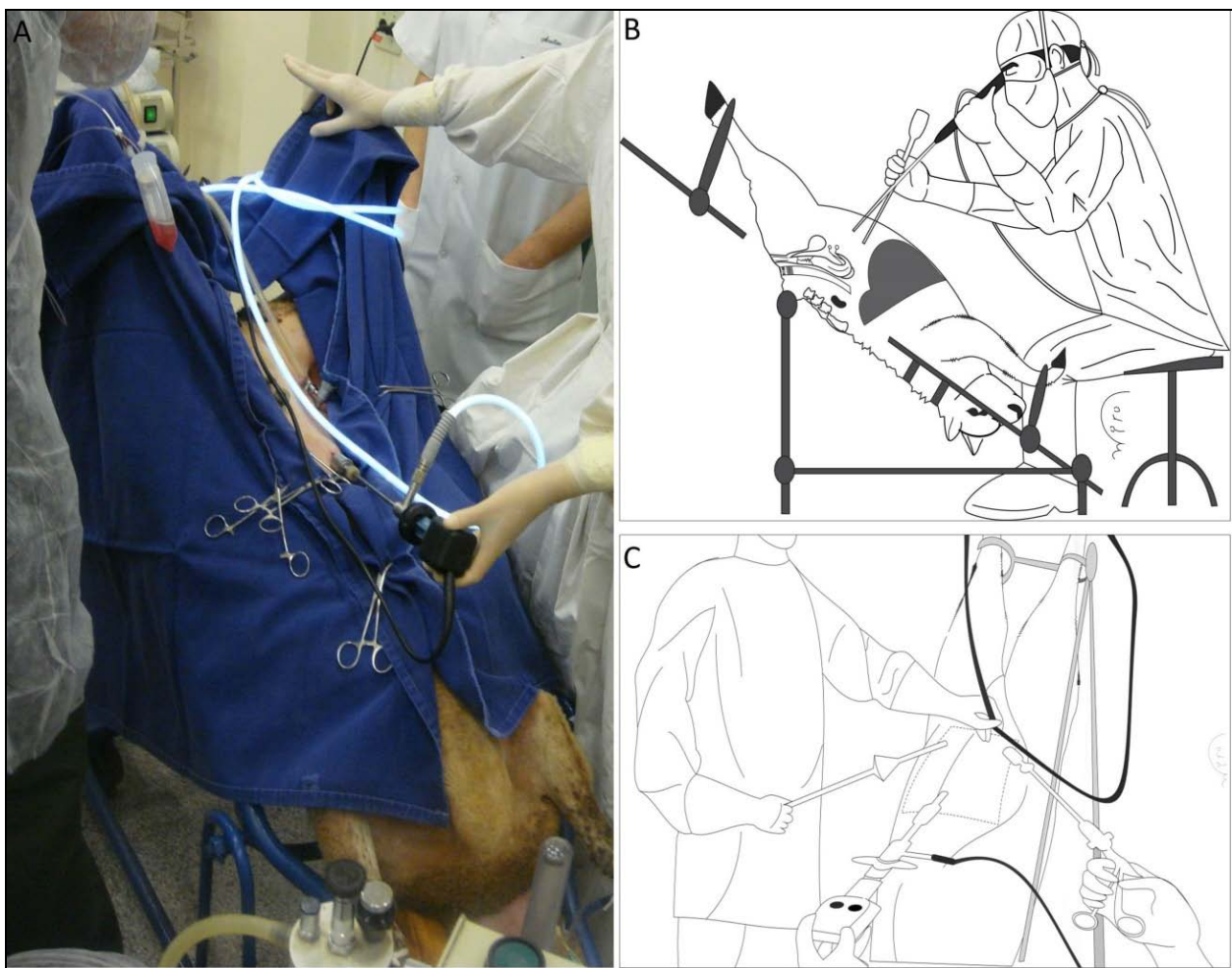


Figure 1. Figure showing the Trendelenburg position used for artificial insemination (AI), embryo transfer (ET) and laparoscopic ovum pick up (LOPU). Observing the 45° slope angle position, side view (B) and front view (A and C). Also showing the two or three videolaparoscope portals, according to the triangular form and facing the inguinal region. Source: personal file.

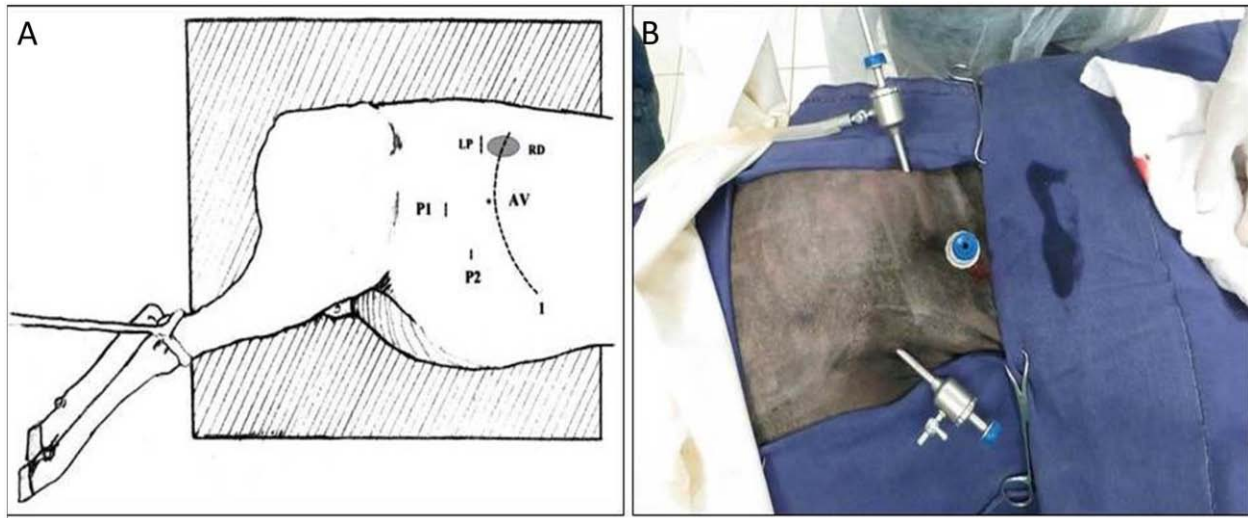


Figure 2. Schematic draw (A) and picture (B) of ovine patient for lateral recumbency position by video laparoscopy. (A) Sites of portals for videolaparoscopy, introduction of Veress needle and laparotomy. (1) Caudal border of the rib cage; (AV) Veress needle introduction site; (P1) First portal site for introduction of the endoscope; (P2) Second portal for introduction of instruments; (LP) Laparotomy site to perform blind biopsy. (RD) Right kidney. (B) Same positioning, but performed the first entry port blind, Positioning Even though the first entry portal performed blind, without the use of a Veress needle. Adapted from Néspoli *et al.*, 2010.

Embryo transfer(ET)

The main goal of embryo transfer is to promote a wide spread of desirable genetic values of the herd, while assuring biosecurity to the herd as natural mating is avoided (Varago *et al.*, 2009).

Superovulation is required, which is usually performed by exogenous administration of FSH in decreasing doses (Traldi, 2006; Varago *et al.*, 2009). In the goat, insemination must be carried out 12-24 h after detection of estrus (Medeiros *et al.*, 2012). In the sheep, AI was recommended 54-56 h after vaginal sponge removal (Rizzo *et al.*, 2009). Laparoscopic insemination should be performed once or twice in a 12 h interval, which increases the rate to around 40 to 70% of success with the use of frozen semen (Varago *et al.*, 2009). Laparoscopy is a safe and accurate technique for embryo collection. The same port placement and patient positioning of AI should be used (Fonseca, 2006).

The two-port technique of intrauterine laparoscopic ET was first described by Schiewe *et al.* (1984). Embryos are collected from donors by washing the uterine horns between the 7 and 8th days following the onset of estrus in goat and the 6 and 7th day in sheep (Traldi, 2006), using a 37°C phosphate buffered saline (PBS) and 1% of fetal bovine serum (FBS) solution per uterine horn (Zanetti, 2009). Two-port access on the *linea alba* is usually performed, placed between the umbilicus and the mammary gland (Fonseca, 2006).

One of the major advantages of laparoscopy use in embryo transfer is the lower incidence of uterine adhesions and easy deposition of the embryo near the utero-tubal junction (Varago *et al.*, 2009). ET success

also depends on the selection of good recipients and donors. Selection criteria should be focused on reproductive tract health, body score and maternal ability (Simplício *et al.*, 2002; Fonseca, 2013).

On average 5 viable embryos are recovered for harvest, both in laparoscopy, laparotomy or by cervix. The laparoscopy advantage compared to laparotomy for the largest number of repetitions, laparotomy is limited to three procedures, as laparoscopy does not have a procedure limit described and can be used for several repetitions in the same female. Transcervical embryo collection technique is limit by the large number of animals with limited cervix passage (Fonseca, 2013; Teixeira *et al.*, 2013).

Ovum pick-up for *in vitro* production

The laparoscopic ovum pick-up (LOPU) is the initial step for *in vitro* embryo production (IVP), with ovulation induction and ovarian stimulation essential for best results of this biotech, especially in females in anestrus or prepubertal. The use of different doses of FSH or eCG is essential to obtain the highest production of follicles. The high hormone doses and the interval between ovarian stimulation and aspirations will be responsible to determine oocyte quality (Baldassarre and Karatzas, 2004; Teixeira *et al.*, 2011b, 2013; Baldassarre, 2012).

Classically, ovaries obtained in slaughterhouses were used to recover oocytes for research purpose, but this method is being replaced by LOPU (Baldassarre, 2012). This new approach allows repeated aspirations and optimal sanitary control (Wani, 2002; Teixeira *et*



al., 2011b; Baldassarre, 2012).

Different treatments were tested for LOPU and "one-shot" is the treatment of choice, because it decreases the interval between the use of the hormone and aspiration. Usually, 70-80 mg of NHI-FSH P1 and 300UI of eCG are administered in a single dose regimen in order to achieve optimal *in vitro* maturation (IVM) of oocytes (Morton *et al.*, 2005). Follicles must be 2-8 mm in diameter for aspiration and present greater cumulus layer for improved fertilization (Crozet *et al.*, 1995; Mermillod *et al.*, 1999, 2008; Baldassarre, 2012; Crocorno *et al.*, 2012).

As for laparoscopic AI and ET, LOPU requires general anesthesia. The most widely used pre-anesthetic protocol in animals submitted to laparoscopy is xylazine 0.05 mg/kg (IM) alone, acepromazine 0.05 mg/kg alone or in combination with midazolam 0.1 mg/kg (IV) and chlorpromazine 1.0 mg/kg (IM) or tramadol 2 mg/kg (Teixeira *et al.*, 2011b). For anesthetic induction, ketamine hydrochloride 2 mg/kg (IV), propofol 3-6 mg/kg (IV) or thiopental 10.5 mg/kg (IV) are used. Anesthetic maintenance should be performed using either halothane or isoflurane vaporized in oxygen (Teixeira *et al.*, 2012) or continuous rate infusion of a mixture of propofol (0.5 mg/kg/min, IV) and lidocaine hydrochloride (1 mg/kg/min, IV; Teixeira *et al.*, 2013).

LOPU is well described using a two-port technique, for insertion of the telescope and a grasping forceps, or three-port access, for the telescope and two forceps. The use of three ports has reduced significantly surgical time in other studies (Teixeira *et al.*, 2011b, 2012).

After aseptic preparation, the patient is positioned in Trendelenburg head tilt, as described for laparoscopic AI and ET. The first trocar is inserted either by open minilaparotomy or blind technique and pneumoperitoneum is established. Veress needle may be used, however increased risk of rumen perforation is advised (Teixeira *et al.*, 2013).

A traumatic graspers, such as Babcock forceps, are used for manipulation of the reproductive tract, including ovaries and uterine horns. For follicle punctures and OPU, a simple vacuum system using a 16G, 18G or 20G needle is more efficient and less traumatic to the cumulus/oophorus complex. The suction pressure of 50-70 mmHg also contributes to oocyte quality (Wieczorek *et al.*, 2010; Crocorno *et al.*, 2012; Padilha *et al.*, 2014).

The LOPU for IVP is still limited due to the need for investment in laboratories. However, it is important to emphasize the applicability also in prepubertal animals and the improvement of herd genetic gain inherent to such technique. In small ruminants, recovery of more than five oocytes per donor is usually achieved, and at the end of the process (LOPU and IVP), achieving 1.2 pregnancies per week (Baldassarre and Karatzas, 2004; Teixeira *et al.*, 2012, 2013).

Ovariectomy

Ovariectomy results in many advantages for animal production, such as (1) improving management by breeding males along with females in the same environment; (2) increasing live weight gain; (3) production of high quality carcass. Furthermore, this technique has also been used to isolate oocytes of animals bearing high genetic and productive performance for assisted reproduction purposes. Laparoscopic ovariectomy requires general anesthesia, aseptic preparation and positioning similar to those for LOPU (Teixeira *et al.*, 2011a, c).

Laparoscopic-assisted ovariectomy requires one or two ports. The use of bipolar coagulation and cutting forceps (Lina Tripol PowerBlade® - WEM & Vivamed) and use of pre-tied ligature was reported for ovariectomy in goats. A relevant factor on laparoscopic ovariectomy is the reduced surgical time compared to the conventional procedure and significantly decreased postoperative pain (Teixeira *et al.*, 2011b, c; Barros *et al.*, 2012).

Cystotomy and cystostomy

Laparoscopic or laparoscopic-assisted cystotomy and cystostomy are feasible in patients presenting obstructions of the urinary tract. Obstructions of the lower urinary tract lead to urinary retention, bladder distention, abdominal pain and urethral or bladder rupture, which usually lead to death by uremia or sepsis (Gheller, 2008). Rupture of the urethra or bladder may occur in 2-3 days following untreated acute obstruction. Other clinical signs include depression, anorexia, pain on palpation of the penile area, tachycardia, tachypnea, anuria or dysuria and hematuria (Riet-Correa *et al.*, 2008).

The obstruction episodes usually occur in goat and sheep during exposures due to energy-rich diet, such as grain and their products, leading to calcium/phosphorus imbalance. Young orchietomized lambs are in increased risk due to poor urethra development. The site of highest obstruction probability is the sigmoid flexure, ischial curvature and urethral process. Urinary obstructions are not common in females due to the shorter and larger diameter of the urethra in comparison to males (Gheller, 2008; Riet-Correa *et al.*, 2008).

Surgical preparation includes fasting for 24 h, wide shaving and aseptic preparation of the abdomen (Franz *et al.*, 2009). The patients are submitted to general anesthesia and subsequently placed in supine position (Gheller, 2008).

A 0.5 cm incision is made 4 cm cranially to umbilicus for optical port placement, while the second portal was made 3 cm lateral right to foreskin and 10 cm distal to umbilicus. The second port is generally placed using laparoscopic guidance, through the prepubic abdominal area, which penetrates the bladder lumen.



Keeping the cannula inside the bladder, a 18-gauge Foley catheter is inserted into the bladder through the trocar cannula and its cuff is inflated to prevent urine leakage. The cannula is then removed, leaving only the Foley catheter into the urinary bladder. The laparotomy is expanded and the bladder is exposed by pulling the Foley catheter for subsequent cystotomy. The bladder is washed with sterile saline solution and routinely sutured using 3-0 monofilament suture material. The bladder is finally replaced into the abdominal cavity and the abdominal wall is routinely closed (Gheller, 2008; Franz *et al.*, 2009).

Postoperative care includes patient monitoring, routine wound care and antibiotic therapy for 7-10 days. The prognosis of the return of urinary and reproductive functions is favorable as the laparoscopic approach maintains the integrity of the urethra and bladder sphincter (Gheller, 2008).

Renal biopsy

Kidney diseases in small ruminants are poorly diagnosed in sheep. However, renal biopsies are useful in studies of pharmacokinetics and toxicology (Toutain *et al.*, 1985).

For laparoscopic-assisted renal biopsy the animals should be submitted to fasting for 12 h. If a right renal biopsy is desired, the animal should be positioned in left lateral recumbence and vice-versa. After abdominal shaving and aseptic preparation, 2% lidocaine hydrochloride is infiltrated at the port site, 10 min prior to incision. A Veress needle is introduced into the abdominal cavity, dorsal and cranially on the flank at the end of the last rib (Fig. 2). A 7-10 mmHg pneumoperitoneum is established and a 6-11 mm trocar is introduced into the abdomen through the skin incision, halfway between the last rib and the coxal tuberosity, for insertion of the telescope. The second port is placed 5-10 cm beside the first trocar, for insertion of laparoscopic scissors. A window is opened on the parietal peritoneum/renal capsule. The scissors are replaced by a Blakesley biopsy forceps and one or more renal samples are taken. Complications such as hemorrhage and fibrosis may occur because of this technique (Néspoli *et al.*, 2010).

Conclusion

Even though laparoscopic techniques still have limited commercial use, clinical and reproductive gains brought by endosurgery are extremely relevant for goat and sheep production. Such biotechnologies should be employed in rural properties, which may improve breeding and cost-effectiveness.

References

Ax RL, Dally MR, Didion BA, Lenz RW, Love CC,

- Varner DD, Hafez B, Bellin ME.** 2004. Inseminação artificial. In: Hafez B, Hafez ESSE (Ed.). *Reprodução Animal*. 7th ed. São Paulo: Manole. pp. 381-394.
- Baldassarre H, Karatzas CN.** 2004. Advanced assisted reproduction technologies (ART) in 33 goats. *Anim Reprod Sci*, 82/83:255-266.
- Baldassarre H.** 2012. Practical aspects for implementing in vitro embryo production and cloning programs in sheep and goats. *Anim Reprod*, 9:188-194.
- Barros FFPC, Teixeira PPM, Silva MAM, Coelho CMM, Lopes MCS, Kawaname AE, Chung DG, Coutinho LN, Padilha LC, Vicente WRR.** 2012. Single-port laparoscopic ovariectomy in Santa Ines ewes using pre-tied loop ligature. *Reprod Domest Anim*, 47 (suppl. 1):76. (abstract).
- Bettencourt EMV.** 1999. *Caracterização de parâmetros reprodutivos nas raças ovinas Merina branca, Merina preta e Campaniça*. Lisboa: Universidade Técnica de Lisboa, Faculdade de Medicina Veterinária. 106 pp. Dissertation.
- Bicudo SD, Azevedo HC, Silva Maia MS, Sousa DB, Rodello L.** 2005. Aspectos peculiares da inseminação artificial em ovinos. *Acta Sci Vet*, 33(suppl.1):127-130.
- Blash S, Schofield M, Echelard Y, Gavin W.** 2012. Update on the first cloned goats. *Nat Biotechnol*, 30:229-230.
- Bouré L.** 2005. General principles of laparoscopy. *Vet Clin North Am Food Anim Pract*, 21:227-249.
- Carneiro GF, Medeiros LRD, Gomes NO.** 2011. *Inseminação artificial em pequenos ruminantes*. Portal ASCAPO. Available on: www.aspaco.org.br/materiais. Accessed on: Apr. 19, 2013.
- Crocomo LF, Marques FWC, Landim FCA, Bicudo SD.** 2012. Peculiaridades da coleta de oócitos para produção in vitro de embriões ovinos. *Rev Bras Reprod Anim*, 36:25-31.
- Crozet N, Ahmed-AliM, Dubos MP.** 1995. Developmental competence of goat oocyte from follicles of different size categories following maturation, fertilization and culture in vitro. *J Reprod Fertil*, 103:293-298.
- Donovan A, Hanrahan JP, Kummer E, Duffy P, Boland P.** 2004. Fertility in the ewe following cervical insemination with fresh or frozen - thawed semen at a natural or synchronised oestrus. *Anim Reprod Sci*, 84:359-368.
- Ferra JC, Sereno JRB.** 2006. *Inseminação Artificial em Ovinos*. Planaltina, DF: Embrapa Cerrados. p.10-11. (Documentos, 156).
- Fonseca JF.** 2006. Alguns aspectos da transferência de embriões em caprinos. *Acta Sci Vet*, 34 (suppl. 1):65-70.
- Fonseca JF.** 2013. *Inseminação Artificial e Transferência de Embriões em Caprinos e Ovinos*. Coronel Pacheco, MG: Embrapa Gado de Leite. 21 pp.
- Franz S, Dadak AM, Schoffmann G, Khol JL, Baumgartner W, Dupre G.** 2009. Laparoscopic-assisted cystotomy: an experimental study in male sheep. *Vet Med*, 54:367-373.



- Gheller V.** 2008. Abordagens laparoscópicas em pequenos ruminantes. *Ciênc Vet Trop*, 11(supl. 2):52-55.
- Kershaw CM, Khalid M, Mc Gowan MR, Ingram K, Leethongdee SG, Scaramuzzi RJ.** 2005. The anatomy of sheep cervix and its influence on the transcervical passage of an inseminating pipette into the uterine lumen. *Theriogenology*, 64:1225-1235.
- Medeiros CHN, Monteiro AWU, Medeiros ALN, Freitas VJF, Salles MGF, Araújo AA.** 2012. Efeito de sucessivos tratamentos superovulatórios com pFSH sobre a resposta ovulatória e produção de embriões de cabras Boer e posterior sobrevivência embrionária após transferência em receptoras sem raça definida. *Rev Bras Hig San Anim*, 6:15-23.
- Mermillod P, Oussaid B, Cognié Y.** 1999. Aspects of follicular and oocyte maturation that affect the developmental potential of embryos. *J Reprod Fertil*, 54:449-460.
- Mermillod P, Dalbiès-Tran R, Uzbekova S.** 2008. Factors affecting oocyte quality: who is driving the follicle? *Reprod Domest Anim*, 43:393-400.
- Morton KM, De Graaf SP, Campbell A.** 2005. Repeated ovum pick-up and in vitro embryo production from adult ewes with and without FSH treatment. *Reprod Domest Anim*, 40:422-428.
- Néspoli PB, Gheller VA, Peixoto PV, Carvalho AU, França TN, Facury Filho EJ, Araújo DKG, Bordin AI.** 2010. Avaliação de técnicas de biópsia renal em ovinos. *Pesq Vet Bras*, 30:260-266.
- Padilha LC, Teixeira PPM, Pires-Buttler EA, Apparício M, Motheo TF, Savi PAP, Nakaghi EYO, Alves AE, Vicente WRR.** 2014. In vitro maturation of oocytes from Santa Ines ewes subjected to consecutive sessions of follicular aspiration by laparoscopy. *Reprod Domest Anim*, 49:243-248.
- Rabassa VR, Tabeleão VC, Pfeifer LFM, Schneider A, Ziguer EA, Schosler E, Severo NC, Del Pino FA, Corrêa MN.** 2007. Efeito das técnicas transcervical e laparoscópica sobre a taxa de prenhez de ovelhas inseminadas em tempo-fixado. *Ciênc Anim Bras*, 8:129-131.
- Riet-Correa F, Simões SVD, Vasconcelos J.** 2008. Urolitíase em caprinos e ovinos. *Pesq Vet Bras*, 28:319-322.
- Rizzo H, François D, Fassier T, Guitton E, Baril G, Cognié J, Fatet A, Guignot F, Mermillod P, Petit JP, Beckers JF, Remy B, Gilles FF, Meyer G.** 2009. Transferência de embriões como ferramenta para formação de rebanho experimental ovino. *Ciênc Anim Bras*, (supl. 1):814-820.
- Schiewe MC, Bush M, Stuart LS, Wildt DE.** 1984. Laparoscopic embryo transfer in domestic sheep a preliminary. *Theriogenology*, 22:675-682.
- Silva TG.** 2009. *Inseminação artificial em ovinos (Ovis aries) por laparoscopia: revisão de literatura*. Curitiba, PR: Universidade Federal do Paraná. Monography.
- Simplício AA, Salles HO, Santos DO.** 2002. Transferência de embriões nos pequenos ruminantes domésticos. *Rev Bras Reprod Anim Supl*, 5:17-23.
- Teixeira PPM, Padilha LC, Motheo TF, Silva MAM, Oliveira MEF, Silva ASL, Barros FFPC, Coutinho LN, Flôres FN, Lopes MCS, Rodrigues LFS, Vicente WRR.** 2011a. Ovariectomy by laparotomy, a video-assisted approach or a complete laparoscopic technique in Santa Ines sheep. *Small Rumin Res*, 99:199-202
- Teixeira PPM, Padilha LC, Oliveira MEF, Motheo TF, Silva ASL, Barros FFPC, Coutinho LN, Flôres FN, Lopes MCS, Bandarra MB, Silva MAM, Vasconcelos RO, Rodrigues LFS, Vicente WRR.** 2011b. Laparoscopic ovum collection in sheep: gross and microscopic evaluation of the ovary and influence on oocyte production. *Anim Reprod Sci*, 127:169-175.
- Teixeira PPM, Silva MAM, Oliveira MEF, Padilha LC, Silva ASL, Barros FFPC, Medeiros RM, Coelho CMM, Rossi A, Lopes MCS, Vicente WRR.** 2011c. Ovariectomia total vídeolaparoscópica em ovelhas pré-púberes. *Vet Zootec*, 18:493-496.
- Teixeira PPM, Silva MAM, Padilha LC, Silva ASL, Barros FFPC, Coutinho LN, Medeiros RM, Kirnew MD, Conceição EM, Vicente WRR.** 2012. Evaluation of serum fibrinogen and total protein in prepubertal sheep subjected to laparoscopic ovum pick-up. *Reprod Domest Anim*, 47(supl. 5):95-95.
- Teixeira PPM, Padilha LC, Mariano RSG, Coutinho LN, Barros FFPC, Silva MAM, Silva ASL.** 2013. Aspiração folicular. In: Oliveira MEF, Teixeira PPM, Vicente WRR. *Biotécnicas Reprodutivas em Ovinos e Caprinos*. São Paulo, SP: MEDVET. vol.1, pp. 147-155.
- Toutain PL, Pomyers H, Larrieu G, Periquet B, More J.** 1985. An in vivo model for pharmacokinetic studies in the kidney. *J Pharmacol Methods*, 14:1-11.
- Traldi AS.** 2006. Biotécnicas aplicadas em reprodução de pequenos ruminantes. In: III Feira Internacional de Caprinos e Ovinos (FEINCO), 2006, São Paulo, SP. São Paulo, SP: FEINCO. 11 pp.
- Valasi L, Fthenakisa GC, Prassinosa NN, Menegatosb I, Grigoropoulouna V, Deligiannisc C, Vainasd E, Amiridisa GS.** 2009. The effect of repeated follicular aspiration on the onset of puberty and growth rate of winter or autumn born lambs. *Small Rumin Res*, 84:35-40.
- Varago FC, Moustacas VS, Cruz BC, Lagares MA, Henry MRJM.** 2009. Biotécnicas da reprodução aplicadas a pequenos ruminantes. *Cienc Anim Bras*, 8(supl. 1):1-17.
- Wani NA.** 2002. In vitro maturation and in vitro fertilization of sheep oocytes. *Small Rumin Res*, 44:89-95.
- Wieczorek J, Kosenyuk Y, Cegla M, Ryńska B.** 2010. A new concept on laparoscopic ovum pick-up (OPU) in sheep: efficiency of method and morphology of recovered oocytes. *Ann Anim Sci*, 10:39-48.
- Zanetti ES.** 2009. *Protocolos de superovulação em veado-catingueiro (Mazama gouazoubira)*. Jaboticabal, SP: Universidade Estadual Paulista, Faculdade de Ciências Agrárias e Veterinárias. Thesis.